TUBERCULOSIS OF THE SKELETAL SYSTEM IN CHILDREN: SPECTRUM OF IMAGING FINDINGS

MELODIA B. GESLANI, MD AND BERNARD F. LAYA, MD, DO

ABSTRACT

Tuberculosis (TB) continues to be a public health concern. It can have both pulmonary and extrapulmonary involvement. Skeletal TB represents up 10-20% of all cases of tuberculosis occurring in extrapulmonary sites. It can manifest as TB spondylitis, which is the most common form, TB arthritis and various forms of TB osteomyelitis. Early diagnosis and prompt treatment are important to prevent serious destruction of the bone and joints as well as the adjacent musculature and soft tissue. Radiological evaluation is often the first step in the diagnostic workup of patients with musculoskeletal TB and further imaging investigations utilizing other modalities are usually based on the findings on the radiograph. The purpose of this article is to present the common manifestations of skeletal TB in children. The spectrum of radiologic manifestation in various imaging modalities will be presented. The pathogenesis and treatment for each disease entity will also be presented for better understanding and clinical correlation.

Author's Affiliations: Melodia B. Geslani, M.D., F.P.C.R., Senior Musculoskeletal Radiologist, Institute of Radiology, St. Luke's Medical Center – Global City, 32nd Street, Bonifacio Global City, Taguig City, Philippines, Telephone: (632) 789-7700, **Email**: mbgeslanimd@yahoo.com; Bernard Laya, M.D., D.O., Associate Professor of Radiology, Director, Institute of Radiology, St. Luke's Medical Center – Global City, 32nd Street, Bonifacio Global City, Taguig City, Philippines, Telephone: (632) 789-7700, **Email:** bernielaya@aol.com

In developed countries, there has been a recorded resurgence of the incidence of skeletal TB since 1985. This has been attributed to a number of factors namely: AIDS, homelessness, a decline in tuberculosis control programs, immigration, and intravenous drug abuse. In some countries, the skeletal lesions of TB have been attributed to Bacille-Calmette-Guerin (BCG) immunization[1]. In the Philippines and many developing countries, TB has remained a major cause of skeletal infection. In endemic areas, children are more likely than adults to be affected, often through exposure to adults infected with TB. Skeletal TB is uncommon and accounts for 10-20% of all extrapulmonary TB and 1-2% of all TB cases[2].

The most common manifestations of skeletal TB in the pediatric age group are: spondylitis, arthritis and osteomyelitis. Hematogenous spread from a primary source is the main route of infection of skeletal TB. The primary source of infection is often unknown and concurrent pulmonary TB is seen in less than 50% of cases[2].

TB SPONDYLITIS

Pathogenesis:

The most common manifestation of skeletal TB is tuberculous spondylitis with 50% of skeletal TB cases involving the spine. It is only less than 50% of these cases wherein active pulmonary disease is present.

The upper lumbar and lower thoracic spine is the most frequently involved and typically, affects more than one vertebra. The vertebral body is more commonly involved than the posterior elements and an anterior predilection of the vertebral body is seen. The disease process begins by deposition of the Mycobacterium via end arterioles into the anterior part of the vertebral body adjacent to either the superior and inferior end-plates. As the infection develops, the cortex is disrupted, spreading the infection to the adjacent disk, subligamentous region or soft tissues. In the vertebral end-plates, demineralization occurs with subsequent resorption and loss of dense margins. There is usually a well-defined margin of destruction but without reactive sclerosis or periosteal reaction in the adjoining vertebral body. As the disease progresses, vertebral collapse develop with anterior wedging leading to the characteristic angulations and gibbus deformity[3]. Seldom are the posterior elements involved by the infection. But when they are, this finding is characteristic of TB, as it is not a feature of pyogenic infections[2].

The infection extends frequently from the vertebra and disks to the adjoining ligaments and soft tissues anterolaterally. Spread of the infection through the subligamentous region leads to multiple levels of skip or contiguous vertebral body involvement. The adjacent disks are involved by spread of the infection by either extension of the infection beneath the anterior or posterior longitudinal ligament, or by penetration of the subchondral plate. Involvement of the disk by the infection occurs late in the disease process, thus preservation of the disk is characteristic of TB. A manifestation of disk involvement however, is narrowing of the intervertebral disk space which is less prominent compared to discitis caused by pyogenic organisms. The infection also extends to the adjacent soft tissues to form paravertebral and epidural masses. It could also spread to the epidural regions, manifesting as masses which may cause neurological complications such as cord compression.

Imaging features:

Early in the disease, radiographs of the spine may be normal or may show mild osteopenia. It is estimated that bone loss of more than 50% must occur before changes are evident on plain radiographs[2] (Figure 1). Later in the disease process, there is progressive vertebral collapse with anterior wedging eventually leading to the gibbus deformity (Figure 2). There is also note of indistinct vertebral end-plates usually with bony erosions and sequestra formation. Narrowing of the disk space occurs when disk involvement occurs. Extension of the infection into the paravertebral soft tissues as paravertebral abscesses in the thoracic region occurs early and seen as posterior mediastinal masses. In the lumbar spine, ilio-psoas abscesses may cause asymmetric bulging of the psoas outline. The psoas abscess may extend to the groin and thigh. If subligamentous spread occurs, there is note of scalloping of the anterior vertebral body.

CT is useful in the demonstrating bony sclerosis particularly of the posterior elements which are difficult to assess on radiographs (Figure 3). It also demonstrates smaller foci of vertebral body involvement and calcifications in healed psoas abscesses which could be difficult to see on radiographs. CT is also useful in interventional procedures including CT guided percutaneous biopsy.

MRI is superior to CT in the demonstration of soft tissue masses, intervertebral disks and spinal cord (Figure 4). MRI is able to detect the early changes in the spine 4-6 months earlier than conventional methods and is also the modality of choice for determining the soft tissue involvement of the disease process. It can give details of the level of cord compression which is important in surgical planning and follow up. Furthermore, it uses no ionizing radiation which is beneficial to the pediatric patient.

Figure 1A

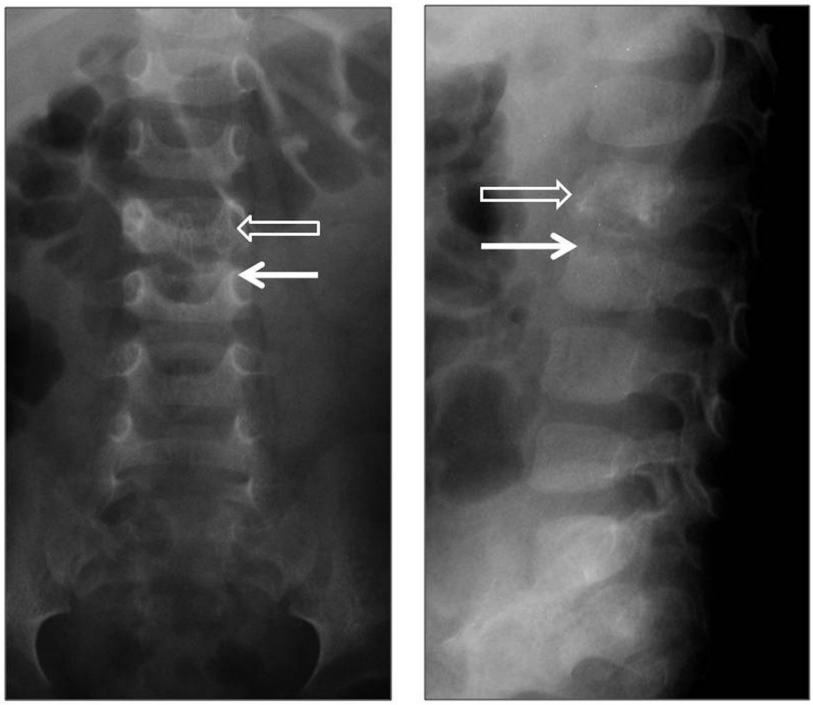

Figure 1B

Figure 1. TB spondylitis on a three year old male. Frontal (Fig. 1 A) and lateral (Fig. 1B) radiographs demonstrate cortical border irregularity of the L2 vertebral body with areas of sclerosis and lucency (open arrow) compatible with TB spondylitis. Subtle cortical irregularity of the superior endplate is also noted at L3 level (solid arrow).

Figure 2A

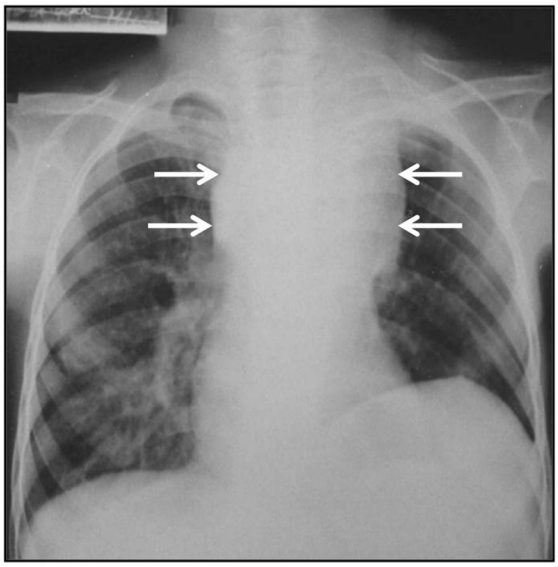

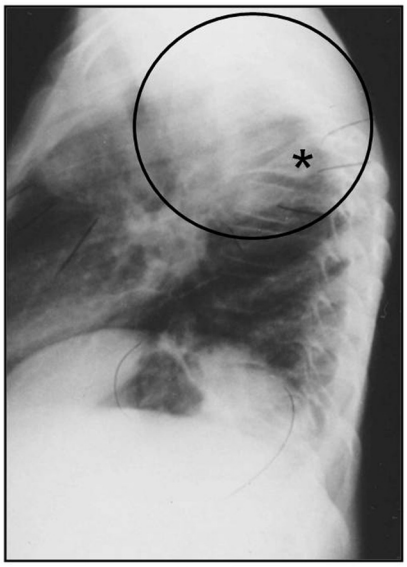

Figure 2B

Figure 2. TB spondylitis with Gibbus deformity. Frontal radiograph (Fig. 2 A) demonstrate paravertebral soft tissue mass in the upper thoracic levels. Lateral view (Fig. 2 B) confirms the paravertebral mass as an increase density in the posterior mediastinum (encircled). Anterior wedge compression deformity of an upper thoracic vertebra (asterisk) is seen with resultant gibbus deformity.

Figure 3A

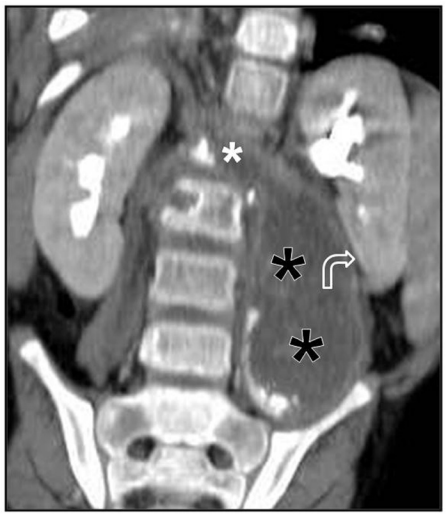

Figure 3B

Figure 3. CT scan in a patient with TB spondylitis. Axial (Fig. 3 A) and coronal reconstruction (Fig. 3 B) CT scan images of the lumbar vertebrae demonstrate fragmentation and resorption of the second lumbar vertebral body as a sequelae of the TB infection (arrows). Soft tissue structure adjacent to the vertebral body are seen compatible with soft tissue inflammation/abscess (asterisks) effacing the left kidney (open arrow).

MRI Findings of TB of the spine are the following: 1) focal areas of decreased signal intensity on T1W images and heterogeneously increased signal intensity on T2W images. 2) early bone marrow changes show enhancement on post-Gd studies 3) chronic bone marrow involvement shows variable signal intensity 4) the signal intensity of the normal disks in children is high signal intensity on T2W images while discitis manifests as low signal intensity of the disks on T2W images 6) post-Gd studies improves assessment of the epidural, paravertebral and prevertebral soft tissue lesions as well as the subligamentous lesions. The demonstration of rim-enhancement of these soft tissue masses has been reported to be diagnostic for TB of the spine[1].

Treatment:

The treatment of spinal TB is conservative with anti-TB regimen. Indications for surgical drainage include large abscesses and impending neurological complications in affected patients.

Figure 4. MRI of TB spondylitis. Sagittal T2 weighted image through the thoraco-lumbar region shows compression fracture of the 10th thoracic vertebra (white asterisk) with associated significant paravertebral inflammatory process (black asterisks). The spinal cord is effaced and posteriorly displaced within the spinal canal (arrow).

TB ARTHRITIS

Pathogenesis:

Tuberculosis of the synovial joints is the second most common site of skeletal TB occurring in 25% of cases[1]. It is usually monoarticular; however, in approximately 10% of patients, multifocal joint involvement occurs. The most commonly involved joints are the hips and the knees. TB of the joints occurs as a result of metaphyseal TB osteomyelitis crossing the epiphyseal plate into the joint. This transphyseal spread is characteristic of TB and is not a feature in pyogenic arthritis. However, in children older than 1.5 years, the communicating vessels between the metaphysis and epiphysis regress thus transphyseal spread is uncommon[2]. A less common route of joint infection is when the organism is deposited directly onto the joint synovium.

Imaging Features:

The Phemister triad of radiographic abnormalities of juxta-articular osteoporosis, peripheral osseous erosions and gradual narrowing of the joint space is highly suggestive of TB of the joint (Figure 5). Other radiographic findings include: joint effusion, osteolytic bone lesions, cortical irregularity and periosteal new bone formation.

Early in the disease process, the joint space is preserved which is due to the lack of proteolytic enzymes in M. tuberculosis. With disease progression, a gradual decrease in joint space is noted but the cartilage destruction may not be evident on radiographs in children with mostly unossified epiphyses. Thus, intact epiphyses on radiographs may underestimate the severity of the underlying pathologic process of cartilage destruction[2]. The peripheral osseous erosions are characteristic of TB in weight-bearing articulations such as the hip, knee and ankle. "Kissing sequestra" or wedge-shaped areas of necrosis are occasionally seen on both sides of the affected joint. A layered periosteal reaction may be seen. Advanced epiphyseal maturity, widening of the intercondylar notch in the knee and periarticular osteopenia are the result of hyperemia. As the disease progresses, cold abscess and sinus tracts may become evident. Marked joint destruction and fibrous or bony ankylosis are manifestations of end-stage disease.

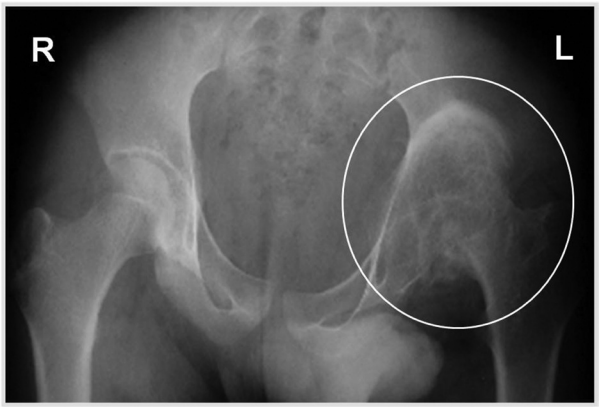

Figure 5. TB Arthritis. Frontal radiograph of the hips and pelvic area shows a grossly abnormal left hip joint with joint space narrowing. The proximal left femur is osteopenic and deformed.

The role of ultrasound in TB arthritis is in the demonstration of the presence of joint effusions and aid in the guidance of the aspiration of these effusions for culture and sensitivity studies. CT may be used for the evaluation of the degree of bone destruction, sequestra and surrounding soft tissue extension.

MRI is the modality of choice for early detection of joint TB. The proliferation of the synovium in TB arthritis is typically hypointense on T2W images, which may be a helpful sign in differentiating it from other proliferative synovial arthropathies. The relatively low signal intensity may be due to the presence of hemorrhage, inflammatory debris, fibrosis, and caseation necrosis. The thickened synovium enhances vividly after the administration of gadolinium[4]. MRI is generally useful in the demonstration of marrow changes, joint effusion, synovitis, pannus formation, and erosions on the cartilage or bone. These lesions are usually seen as low signal on T1W images and high signal on T2W images. The gradient echo (GRE) sequence is useful in the evaluation of the cartilage. Ad-

ministration of Gadolinium causes marked to moderate enhancement of the synovium in acute synovitis but in chronic synovitis, the synovium may not show enhancement. Pyogenic and juvenile idiopathic arthritis may have similar imaging features, and aspiration or synovial biopsy is needed for definitive diagnosis of TB.

Treatment:

The goal of treatment is to cure the infection by the TB mycobacterium with anti-TB drugs. Due to the frequency of isoniazid resistance, treatment initially involves a combination of four drugs: Isoniazid, Rifampin, Pyrazinamide, Streptomycin or Ethambutol. The usual anti-tuberculous drug therapy of at least 9 months duration is longer in children and immunocompromised hosts. Partial synovectomy and other surgical procedures should be restricted to joints with severe cartilage destruction, large abscesses, joint deformity, multiple drug resistance or atypical mycobacteria[5, 6].

TB OSTEOMYELITIS

Pathogenesis:

Tuberculous osteomyelitis is less common than TB spondylitis or TB arthritis. It has been reported that the vertebrae is the site of skeletal infection in 50% of patients, the synovium in 25% and the bone in 11% of children[(4)]. Previously, the lesions of TB osteomyelitis were those of the multifocal, disseminated and destructive type (Jungling disease) which almost always occurs secondary to hematogenous spread from a primary focus. In 75% of the patients, the primary focus is the lungs. Recently, however, isolated bone lesions are more commonly seen in children. A primary lung focus is often not present[2].

Most commonly involved sites are the skull vault, hands, feet and ribs[2]. The metaphyses of the long bones appear to be the common site of involvement. At the site of deposition of the mycobacterium within the bone, a granulomatous lesion develops. This granulomatous lesion develops into an expanding caseating focus which subsequently causes trabecular destruction. Cortical destruction then periosteal reaction may subsequently occur followed by the development of a soft tissue mass.

Children with bone lesions usually present with signs and symptoms such as local pain, swelling, tenderness, muscle wasting, and decreased range of movement. Delays in the diagnosis of these primary bone lesions in children happen because the symptoms are subtle. Also, the variable radiologic picture of these isolated bone lesions may mimic subacute and chronic pyogenic osteomyelitis, fungal infections, cartilaginous tumors, simple and aneurysmal bone cysts, osteoid osteoma, eosinophilic granuloma, and Ewing sarcoma. Thus, the lack of familiarity with the spectrum of the isolated bone lesions may cause a delay in diagnosis.

Trauma and impaired host resistance has been suspected to play an important in the pathogenesis of bone tuberculosis. After a minor trauma, the previously asymptomatic and dormant lesions may be activated. The trauma masks the underlying pathology causing a delay in diagnosis. Impaired host resistance may also activate dormant lesions.

Some reported that the bone lesions are usually solitary because sensitization of the patient to tubercle bacillus occurred before the onset of the skeletal disease. But if the host immunity is poor and the immune resistance has been altered, the lesions may multiply.

Imaging Features:

There are four (4) basic types of bone lesions associated with TB osteomyelitis such as 1) cystic, 2) infiltrative, 3) focal erosions, and 4) spina ventosa[1]. Although four basic forms of bone changes are described, there can be a combination of two or more types in some patients, with one type usually predominating.

The cystic form is the most common form of these isolated bone lesions. In children, these were more commonly localized in long bones and flat bones as single or multiple foci. These bone lesions are well-defined, round to ovoid, radiolucent lesions seen in the peripheral skeleton near the metaphyses. Marginal sclerosis is seen in some cases which causes the cystic appearance. Expansion of the bones and honeycombing is sometimes seen. A sequestrum of necrotic cancellous bone may be present within the cavity. These cysts may cross the epiphyseal plate to involve the epiphysis[1]. These cystic bone lesions can mimic various benign bone tumors and granulomatous bone lesions (Figure 6).

The infiltrative form of bone lesion is seen as a more diffuse area of bone destruction with permeation and little or no periosteal reaction. These forms of bone lesions may resemble chronic pyogenic osteomyelitis, fungal infection and Ewing Sarcoma[1] (Figure 7). Another form of TB osteomyelitis includes those lesions manifesting as small, focal erosions which are localized areas of osteolysis. These are usually situated eccentrically with or without destruction of the cortex. Some of the lesions are described as punched-out defects with marginal sclerosis while the others are described as localized areas of bone destruction with slight periosteal reaction without marginal sclerosis (Figure 8). These bone lesions may resemble or mimic pyogenic osteomyelitis, eosinophilic granuloma, nonossifying fibroma, and neuroblastoma[1].

The expansile lesions are the least common and results from underlying bone destruction with periosteal thickening and fusiform expansion of the bone. This appearance gives the term spina ventosa (spina = short

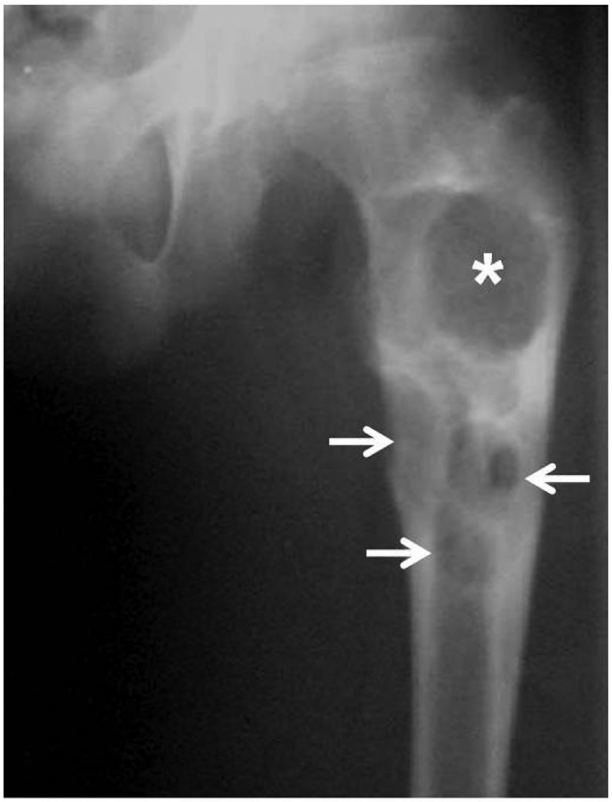

Figure 6. Cystic form of TB osteomyelitis. Frontal radiograph of the left proximal femur shows a large well-defined lucent bone defect (asterisk) and a few smaller cystic defects. There is expansion of the bone but no significant periosteal reaction.

bone, ventosa = filled with air). These bone lesions appear radiographically like cystic cavities with expansion of the diaphysis. Sequestrum formation may occur. There is usually overlying soft tissue swelling, seen both clinically and radiographically. These bone lesions are commonly seen in the short tubular bones of the hands and feet where the condition is called TB dactylitis[2] (Figure 9). These lesions may also involve the forearm bones and the clavicles[1]. In children, this form of bone lesion shows multiple sites of involvement, whereas in adults, a single bone is usually involved.

MRI is an excellent modality for demonstrating TB osteomyelitis especially during its early phase. MRI shows marrow changes as areas of low signal intensity on T1-W imaging and high signal intensity on T2-W images. Enhancement of these areas of marrow involvement is noted after the administration of Gd-DTPA. Extension into the adjacent soft tissues can be seen in some patients with extensive disease and pattern of enhancement could be intense and heterogenous. In such cases, differentiation between tuberculosis and other infectious etiologies as well as neoplastic processes can be challenging.

Treatment:

As the radiological features of osseous TB are not pathognomonic, tissue diagnosis with curettage and synovial biopsy is necessary to establish the diagnosis. Curettage and debridement of cavities and bone defects where bacilli are sequestered in necrotic tissue yields favorable results. Biopsy will also exclude pyogenic and fungal infections.

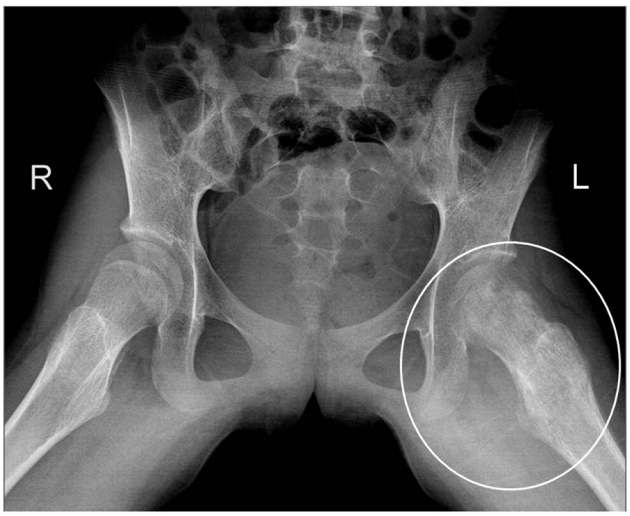

Figure 7A

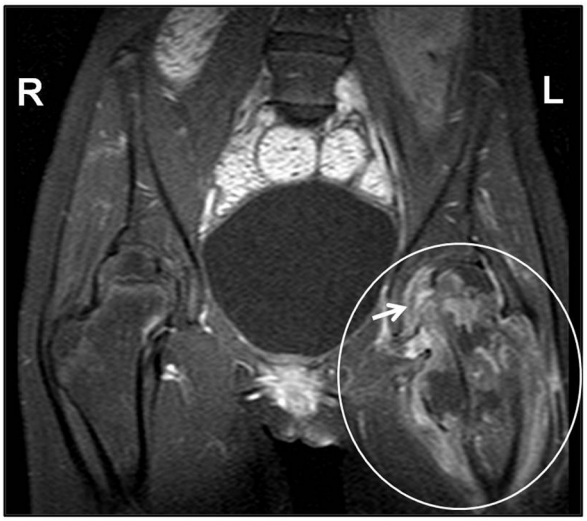

Figure 7B

Figure 7. Permeated form of TB osteomyelitis. Fig. 7 A is a frontal radiograph of the hips that shows demineralized left proximal femur with permeated appearance of the bone matrix. Fig. 7 B is a contrast enhanced T1 image with fat saturation showing a geographic pattern of enhancement of the left proximal femur with enhancing soft tissue component. Extension of the infection into the joint space (arrow) is also noted.

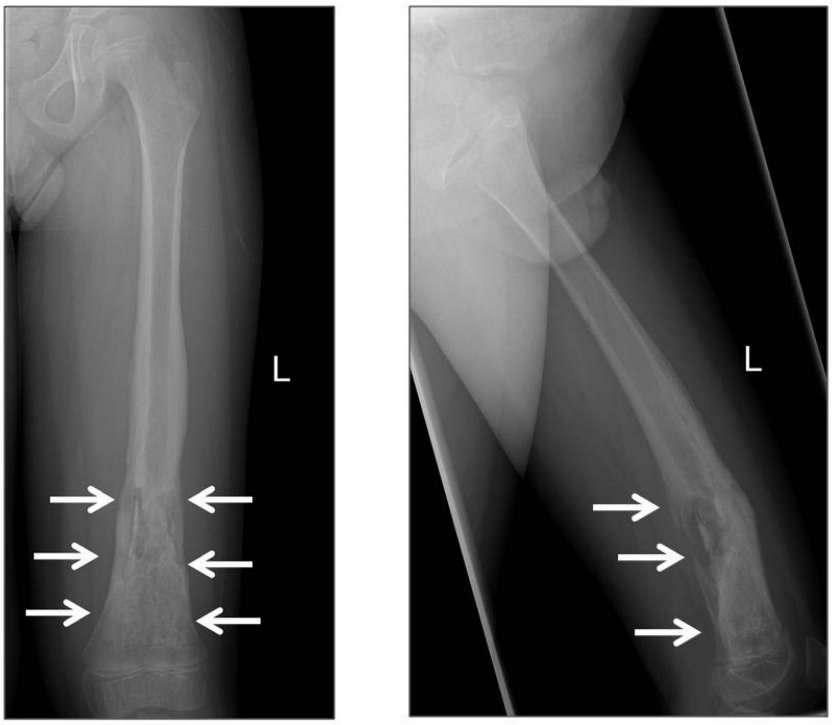

Figure 8A **Figure 8B**

Figure 8. Erosive form of TB osteomyelitis. Frontal (Fig. 8 A) and lateral (Fig. 8 B) radiographs of the left distal femur demonstrate osteopenia and expansion of the distal metadiaphyseal region with cortical erosions and periosteal reaction.

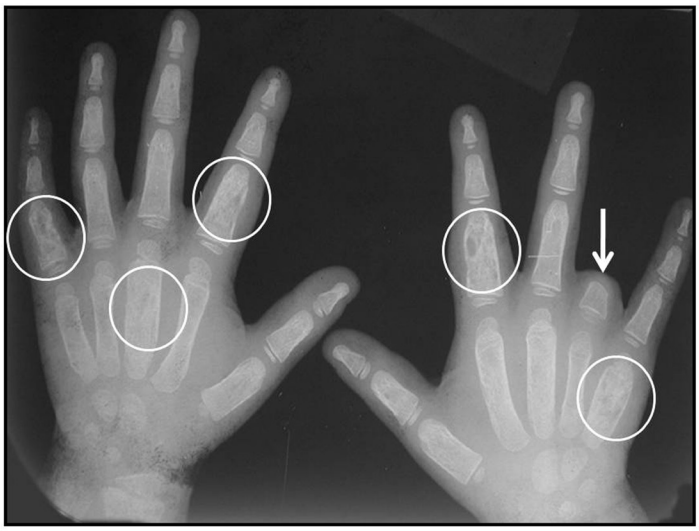

Figure 8. Erosive form of TB osteomyelitis. Frontal (Fig. 8 A) and lateral (Fig. 8 B) radiographs of the left distal femur demonstrate osteopenia and expansion of the distal metadiaphyseal region with cortical erosions and periosteal reaction.

Antitubercular drugs are the mainstay of therapy. Curettage of affected bone in selected cases of cystic forms of bone lesions may promote early healing. Response to therapy is excellent and the overall prognosis is good, as reported in some case series[7]. Bone grafting of defects has also been suggested with demonstration of good resolution and remodeling of the involved bone in some series[1].

BCG OSTEOMYELITIS

Bacille-Calmette-Guerin (BCG) Osteomyelitis manifests with radiographic features similar to TB osteomyelitis. The epiphysis and metaphysis are the usual sites of involvement and may cross the growth plate. Symptoms of BCG Osteomyelitis usually manifests during a period ranging from a few months to 5 years post-vaccination. Diagnosis requires the culture of the BCG strain and a negative guinea pig test.

CONCLUSION

Musculoskeletal involvement is still a very important extension of TB disease. The clinical presentation is as diverse as its imaging manifestations, ranging from subclinical disease to overt and extensive disease. Although histologic correlation maybe necessary in some cases for a more definitive diagnosis, medical imaging plays an important role in establishing the diagnosis, for anatomic localization of disease and follow-up during and after therapy.

REFERENCES

1. Rasool, M.N. (2001). Osseous Manifestations of Tuberculosis in Children. Journal of Pediatric Orthopedics 21: 749-755
2. Teo, H.E.L., Peh, WC.G. (2004) Skeletal Tuberculosis in Children. Pediatric Radiology 34: 853-860
3. Harisinghani, M.G., Mcloud, T.C., Shepard, J.O., *et al* (2000). TB From Head to Toe. Radiographics 20: 449-470
4. Vanhoenacker, F.M., Sanghvi, D.A., De Backer, A.I. (2009) Imaging Features of Extraaxial Musculoskeletal Tuberculosis. Indian Journal of Radiologic Imaging Aug; 19(3): 176-186
5. Malaviya AN, Kotwal PP. (2003) Arthritis Associated with Tuberculosis. Best Pract Res Clin Rheumatol. Apr;17(2):319-4
6. Sequeira W, Co H, Block JA. (200) Osteoarticular tuberculosis: current diagnosis and treatment. Am J Ther. Nov;7(6):393-8
7. Malik S, Joshi S, Tank JS. (2009). Cystic bone tuberculosis in children--a case series. Indian J Tuberc. Oct;56(4):220-4